Official Journal of the Asian Pacific Society of Respirology
Respirology

INVITED REVIEW SERIES:
IDIOPATHIC INTERSTITIAL PNEUMONIA—PART 1: OVERVIEW
SERIES EDITORS: TAMERA J CORTE, ATHOL U WELLS AND HAROLD R COLLARD

Invasive diagnostic techniques in idiopathic interstitial pneumonias

VENERINO POLETTI,[1,2] CLAUDIA RAVAGLIA,[1] CARLO GURIOLI,[1] SARA PICIUCCHI,[3] ALESSANDRA DUBINI,[4] ALBERTO CAVAZZA,[5] MARCO CHILOSI,[6] ANDREA ROSSI[7] AND SARA TOMASSETTI[1]

[1]*Pulmonology Unit, Department of Thoracic Diseases, Departments of* [3]*Radiology and* [4]*Pathology, GB Morgagni–L Pierantoni Hospital, Forlì,* [5]*Operative Unit of Pathology, S. Maria Nuova Hospital, Reggio Emilia,* [6]*Department of Pathology, Verona University,* [7]*Pulmonary Unit, University of Verona, Verona, Italy, and* [2]*Department of Respiratory Diseases and Allergology, Aarhus University Hospital, Aarhus, Denmark*

ABSTRACT

Fibrosing interstitial lung diseases (f-ILDs) represent a heterogeneous group of disorders in which the aetiology may be identified or, not infrequently, remain unknown. Establishing a correct diagnosis of a distinct f-ILD requires a multidisciplinary approach, integrating clinical profile, physiological and laboratory data, radiological appearance and, when appropriate, histological findings. Surgical lung biopsy is still considered the most important diagnostic tool as it is able to provide lung samples large enough for identification of complex patterns such as usual interstitial pneumonitis (UIP) and nonspecific interstitial pneumonitis. However, this procedure is accompanied by significant morbidity and mortality. Bronchoalveolar lavage is still a popular diagnostic tool allowing identification of alternative diagnoses in patients with suspected idiopathic pulmonary fibrosis (IPF) when an increase in lymphocytes is detected. Conventional transbronchial lung biopsy has a very low sensitivity in detecting the UIP pattern and its role in this clinical-radiological context is marginal. The introduction of less invasive methods such as transbronchial cryobiopsy show great promise to clinical practice as they can be used to obtain samples large enough to morphologically support a diagnosis of IPF or other idiopathic interstitial pneumonias, along with fewer complications. Recent advances in the field suggest that less invasive methods of lung sampling, without significant side effects, in combination with other diagnostic methods could replace the need for surgical lung biopsy in the future. Indeed, these new multidisciplinary procedures may become the main diagnostic work-up method for patients with suspected idiopathic interstitial pneumonia.

Key words: bronchoscopy and interventional techniques, interstitial lung disease.

Abbreviations: BAL, bronchoalveolar lavage; CT, computed tomography; DIP, desquamative interstitial pneumonia; f-ILDs, fibrosing interstitial lung diseases; FNA, fine needle aspiration; HP, hypersensitivity pneumonitis; HRCT, high-resolution computed tomography; IPF, idiopathic pulmonary fibrosis; NSIP, nonspecific interstitial pneumonitis; SLB, surgical lung biopsy; TBB, transbronchial lung biopsy; UIP, usual interstitial pneumonitis.

Correspondence: Venerino Poletti, Pulmonology Unit, Department of Thoracic Diseases, GB Morgagni–L Pierantoni Hospital, Via Carlo Forlanini, 34, Forlìì 47100, Italy. Email: venerino.poletti@gmail.com

The Authors: Venerino Poletti is Professor and Chair at the Department of Respiratory Diseases and Allergology, Aarhus University Hospital, Denmark, and Chair at the Pulmonology Unit, Department of Thoracic Diseases at GB Morgagni–L Pierantoni Hospital, Forlì, Italy. He is an expert in diffuse parenchymal lung diseases (DPLD) and interventional pulmonology. Claudia Ravaglia is a Pulmonologist at GB Morgagni–L Pierantoni Hospital, Forlì, Italy. She has an interest in diffuse parenchymal lung diseases (DPLD) and interventional pulmonology. Carlo Gurioli is a Pulmonologist at GB Morgagni–L Pierantoni Hospital, Forlì, Italy. He has an interest in interventional pulmonology. Sara Piciucchi is a Radiologist at GB Morgagni–L Pierantoni Hospital, Forlì, Italy. She has an interest in diffuse parenchymal lung diseases (DPLD). Alessandra Dubini is a Pathologist at GB Morgagni–L Pierantoni Hospital, Forlì, Italy. She has an interest in diffuse parenchymal lung diseases (DPLD). Alberto Cavazza is Director of the Pathology Department at S. Maria Nuova Hospital, Reggio Emilia, Italy. He is an expert in Thoracic Pathology. Marco Chilosi is Professor and Chair at the Pathology Department, Verona University, Verona, Italy. His research includes molecular morphology, immunohistochemistry, molecular biology, lung pathology and haematopathology. Andrea Rossi is Professor and Chair at the Department of Respiratory Diseases, Verona University, Verona, Italy. Sara Tomassetti is a Pulmonologist at GB Morgagni–L Pierantoni Hospital, Forlì, Italy. She has an interest in diffuse parenchymal lung diseases (DPLD) and interventional pulmonology.

Received 10 November 2014; invited to revise 26 July and 14 October 2015; revised 2 September and 28 October 2015; accepted 29 October 2015.

© 2015 Asian Pacific Society of Respirology

Table 1 Idiopathic interstitial pneumonias: typical clinical-radiologic aspects

	Clinical profile	HRCT scan features
IPF	Dyspnoea/dry cough/chronic onset/digital clubbing/elderly former smokers (predominantly males)	Bibasilar honeycombing in the subpleural sites
NSIP	Dyspnoea/cough/low-grade fever/subacute onset/middle-aged nonsmoker females	Ground glass/subpleural sparing/perilobular pattern (Fig. 1)
RB-ILD	Middle-aged or young smokers Mild symptoms/mild DLCO impairment	Centrilobular nodules in the upper lobes

DLCO, diffusing capacity of the lung for carbon monoxide; HRCT, high-resolution computed tomography; IPF, idiopathic pulmonary fibrosis; NSIP, nonspecific interstitial pneumonitis; RB-ILD, respiratory bronchiolitis – interstitial lung disease.

INTRODUCTION

The diagnostic approach to fibrosing interstitial lung diseases (f-ILDs) is a step-by-step process, and invasive procedures are considered only when clinical scenario, laboratory tests and high-resolution computed tomography (HRCT) scan features are inconclusive.[1–3] Pulmonologists can utilize a large array of invasive procedures including bronchoalveolar lavage (BAL), endobronchial biopsy, transbronchial lung biopsy with conventional forceps (TBB) or cryoprobes (c-TBB), blind or ultrasound-guided transbronchial biopsies/aspiration (TBNA, EBUS), oesophageal echoendoscopic biopsies/aspiration (EUS),[4–6] trans-thoracic biopsies (computed tomography (CT) or ultrasound guided) or medical thoracoscopy.[1] Surgical lung biopsy (SLB) provides substantial lung tissue but complications related to this procedure are considerable.

THE MULTIDISCIPLINARY APPROACH

Interstitial pneumonias represent a group of disorders characterized by heterogeneous clinical profiles, laboratory and CT scan features.[3] The majority of these disorders are chronic and patients present with subtle symptoms at diagnosis, mainly limited to the lungs. A minority may present with rapidly progressive symptoms/signs not limited to the lungs, leading rapidly to respiratory failure. The disease can derive from a systemic disorder that involves the lung or may be linked to an identifiable triggering cause. When clinical features or serologic tests are suggestive of but not definitive for connective tissue disease, the designation of interstitial pneumonia with autoimmune features has been suggested.[7] Only when specific systemic background or causes cannot be identified should the term idiopathic or cryptogenetic be used. Currently, it is thought that a combination of clinical profile, laboratory tests and HRCT scan features may be diagnostic in more than 50% of patients in the context of an idiopathic entity[8] (Table 1) (Fig. 1). HRCT can have a pivotal role: bibasilar subpleural honeycombing is pathognomonic of usual interstitial pneumonitis (UIP) pattern[8] and subpleural sparing is characteristic of nonspecific interstitial pneumonitis (NSIP).[8,9] However, accurate identification of honeycombing is sometimes difficult due to the presence of other conditions that can mimic honeycombing (e.g. emphysema, traction bronchiectasis).[10] When honeycombing changes are not detectable, subpleural bibasilar reticulation is considered suggestive of UIP pattern, but further information (mainly provided by a SLB) is deemed necessary[3,8–10] (Fig. 2). The role of less invasive procedures (mainly c-TBB) in documenting complex morphological patterns is debated due to a lack of experience in the majority of centres and a lack of high-quality evidence.[4,11]

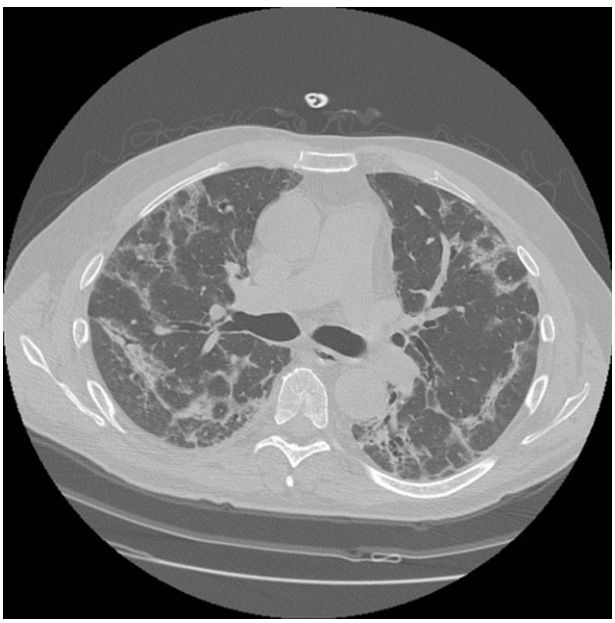

Figure 1 54-year-old female with subacute onset of dyspnea, dry cough and mild fever. High-resolution computed tomography scan features: bilateral perilobular pattern and little bronchiectasis in the periphery of middle zones of both lungs. Mild ground glass attenuation with a perilobular distribution is also present.

In clinical practice the gap between the 'perfect diagnosis' (truth) and the 'possible diagnosis' for each patient is influenced by the relationship between risks/benefits of the diagnostic tools and therapeutic choices available.[12] Such considerations need to be discussed with the patient and different approaches

 © 2015 Asian Pacific Society of Respirology

14401843, 2016, 1, Downloaded from https://onlinelibrary.wiley.com/doi/10.1111/resp.12694 by Universitatsbibliothek RWTH Aachen University, Wiley Online Library on [06/03/2026]. See the Terms and Conditions (https://onlinelibrary.wiley.com/terms-and-conditions) on Wiley Online Library for rules of use; OA articles are governed by the applicable Creative Commons License

Figure 2 Possible usual interstitial pneumonitis pattern with a mild peripheral reticulation and moderate architectural secondary lobule distorsion in both lower lobes. In right lower lobe, a focal dendriform calcification is present. No honeycombing is visible.

adopted. Specific or even genetic biomarkers may be used in specialized centres (telomerase mutations or MUC5B polymorphisms for patients with suspected idiopathic pulmonary fibrosis (IPF))[13,14] and may change the clinical perception of the disease. Clinical evolution may also be used to reach a diagnosis: functional decline, imaging features and laboratory tests changes during follow-up.[3] When the patient's condition permits, observing the clinical development of the disease over a follow-up period can be considered a good compromise between disease progression and the need for more invasive procedures at the onset of the disease.

INVASIVE PROCEDURES

BAL

Recognition of an inflammatory cellular pattern (increased lymphocytes, eosinophils or neutrophils) in the BAL frequently helps clinicians to narrow the differential diagnosis of f-ILDs, even though such patterns are non-specific. Increased lymphocytes suggest an alternative diagnosis to IPF[15,16] and may be observed in idiopathic NSIP (mainly in cellular NSIP or in NSIP where alveolar opacifications are present in the HRCT scan), cryptogenic-organizing pneumonia, hypersensitivity pneumonitis (HP) and lymphocytic interstitial pneumonia.[1] Smoking-related ILDs, mainly desquamative interstitial pneumonia (DIP), are characterized by the presence of 'smoker's' macrophages and increased eosinophils, often at levels as high as seen in eosinophilic pneumonia.[17] BAL lymphocyte subsets have been examined extensively in sarcoidosis and HP: a CD4/CD8 ratio >3.5 was reported to be very specific for sarcoidosis in a characteristic clinical-radiologic context;[18,19] subacute HP usually presents with a reduced CD4/CD8 ratio.[1] Recent guidelines from the American Thoracic Society/European Respiratory Society on IPF suggest avoiding BAL in subjects with suspected IPF.[20] This suggestion is however open to criticism: in a minority of cases with HRCT scan typical for UIP, an alternative diagnosis such as chronic HP or idiopathic NSIP may be considered after the detection of an increased lymphocyte count in BAL;[16] when atypical clinical-radiological features are predominant, alternative diagnoses need to be considered and BAL could contribute to the collection of useful information with low risk for the patients. BAL is also useful to indicate unexpected diagnoses in cases mimicking f-ILDs such as disseminated lung malignancies including lymphomas, eosinophilic pneumonia, alveolar proteinosis, Langerhans cell histiocytosis, chronic alveolar haemorrhage, exogenous lipoidic pneumonia, dust exposure (asbestos exposure) and bronchiolitis.[1,19,21–23] BAL has also a role in the diagnostic work-up of patients with f-ILD and may provide additional information in patients who cannot, or will not agree to, be subjected to more invasive procedures—in a minority of cases, the procedure may suggest an alternative diagnosis. BAL may also have a prognostic value:[24] increased neutrophils with a low lymphocyte count suggest a bad prognosis in chronic HP and increased neutrophils have been reported to predict mortality in IPF.

TBB and transbronchial cryobiopsy

Andersen *et al.*[25] are credited with the first description of TBLB following their observation that bronchial biopsy specimens of small airways harvested during rigid bronchoscopy often contained lung parenchyma. The forceps used in conventional TBLB reach lung tissue through the bronchial routes and specimens come from the centrilobular regions.[1] The disorders that are centred around terminal and respiratory bronchioles or significantly involve these structures (OP) or are distributed along the lymphatic routes (sarcoidosis, carcinomatous lymphangitis) may be easily sampled by the forceps. In 'lymphangitic' disorders, bronchial biopsies may also contribute to increasing diagnostic accuracy. TBLB specimens may contain very specific and informative lesions (also using immunohistochemical staining) that are diagnostic by themselves (e.g. carcinomatous lymphangitis, other neoplasms, lymphangioleiomyomatosis or Langerhans cell histiocytosis). Alternatively, TBLB specimens may show characteristic, but not specific, features that may be considered diagnostic only after discussion of the clinico-radiologic context (e.g. OP, sarcoidosis, HP). Finally, they may not be informative when morphologic findings are completely incongruous with the clinical-radiologic context.[26,27] The diagnostic role of conventional TBLB in IPF and other idiopathic fibrotic interstitial pneumonias is extremely important. Berbescu *et al.*[28] reported that the hallmarks of

© 2015 Asian Pacific Society of Respirology

14401843, 2016, 1, Downloaded from https://onlinelibrary.wiley.com/doi/10.1111/resp.12694 by Universitatsbibliothek RWTH Aachen University, Wiley Online Library on [06/03/2026]. See the Terms and Conditions (https://onlinelibrary.wiley.com/terms-and-conditions) on Wiley Online Library for rules of use; OA articles are governed by the applicable Creative Commons License

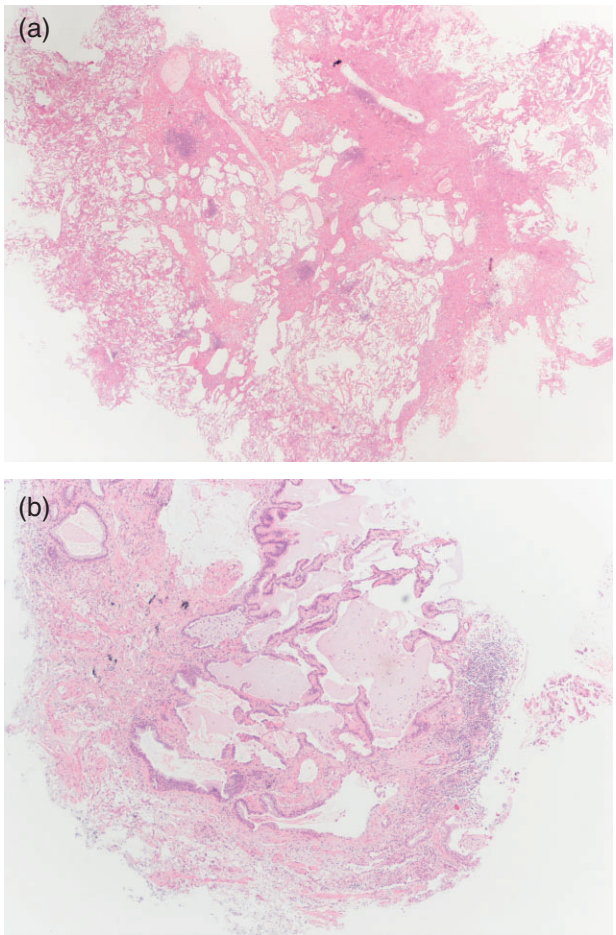

Figure 3 (a) Transbronchial cryobiopsy. Usual interstitial pneumonitis (UIP) pattern: normal lung abutting with fibrotic lung. Scattered fibroblastic foci are also present (HE, low power). (b) Transbronchial cryobiopsy. UIP pattern: subpleural honeycomb changes (HE, mid power).

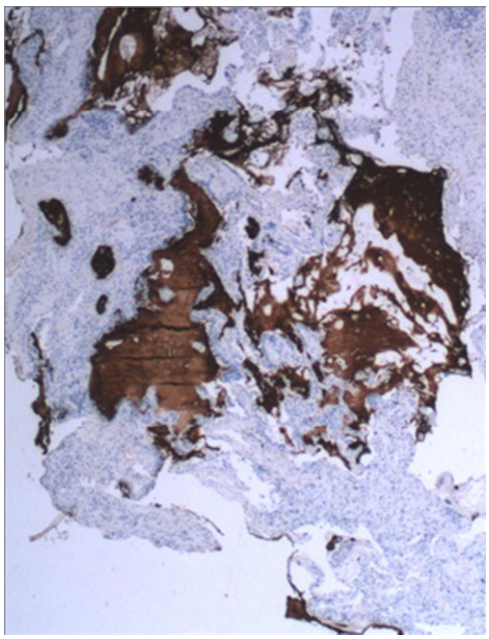

Figure 4 Usual interstitial pneumonitis pattern. Transbronchial cryopsy sample. Immunohistochemistry documenting accumulation of MUC5b mucin in the cystic spaces (anti MUC5b, mid power).

UIP (honeycombing, patchy fibrosis and fibroblastic foci) may be identified in TBLB samples. Tomassetti *et al.*[29] confirmed this observation but showed that the sensitivity of the procedure is very low and that other patterns such as NSIP and DIP provide a very low negative predictive value (i.e. when these patterns are identified in tiny TBB specimens, the probability remains high of a diagnosis of UIP in larger samples). The procedure has a low complication rate: pneumothorax occurs in up to 8% of cases,[1,29] major bleeding in less than 1% of cases and other complications (acute exacerbation of fibrotic lung disease, air embolism) even more rarely.[30]

More recently, cryoprobes have been used to obtain lung tissue[4] and studies of their clinical role in f-ILDs are starting to show promising results. Samples obtained through c-TBB are usually 40–50 mm^2 in size and contain peripheral structures of the secondary pulmonary lobules.[31] Recognition of UIP pattern on these large specimens has good inter-observer variability index and may be recognized by pathologists with high confidence (Fig. 3).[5] Immunohistochemical analysis may be carried out easily in samples obtained by cryobiopsy. In the near future new markers such as laminin-5-gamma2-chain, fascin, heat shock protein 27, beta-cateninn and MUC5b (Fig. 4) will provide additional useful information on the morphological background of IPF.[13,14] Less high-quality evidence studies are available for other patterns such as NSIP and DIP, but the combination of morphological information provided by c-TBB and BAL profiles might be considered diagnostic and thereby avoid a SLB. Indeed the value of c-TBB, in combination with other clinical findings in the context of a multidisciplinary discussion, was found to be similar to that reported for SLB.[32]

It is clear that transbronchial cryobiopsy instead of regular TBB can be considered a potential alternative to SLB. However, studies on the standardization of the procedure are still absent.[31] The bioptic sample size is many times greater than that obtained by regular TBB and is representative also of the periphery of the secondary pulmonary lobule. Improved results are seen in 'intubated patients' and when biopsies are taken within 1 cm of the pleura. In studies to date, the sample size appears to be larger when larger cryoprobes or a freezing time >4 s are used. The routine use of bronchial blockers (e.g. Fogarty balloon or another blocker) appears to prevent the potentially dangerous effects of any major bleeding.[33] The rate of pneumothorax varies in different studies and seems to be higher when biopsies are obtained just beneath the pleura or in subjects with the UIP pattern (a higher pneumothorax rate of 28% was reported by Casoni and coworkers, but in this study the biopsies were obtained at a maximum of 1 cm distance from

 © 2015 Asian Pacific Society of Respirology

14401843, 2016, 1, Downloaded from https://onlinelibrary.wiley.com/doi/10.1111/resp.12694 by Universitatsbibliothek RWTH Aachen University, Wiley Online Library on [06/03/2026]. See the Terms and Conditions (https://onlinelibrary.wiley.com/terms-and-conditions) on Wiley Online Library for rules of use; OA articles are governed by the applicable Creative Commons License

the pleura and samples showed a UIP pattern in 75% of cases).[5] The strategies used to collect samples are not yet standardized,[31] with the majority of studies to date having retrieved lung tissue from one segment and only a minority have collected lung samples from different segments of the same lobe.[4] No prospective studies have yet been published comparing these two approaches in terms of diagnostic yield and rate of complications. Even less information is available on biopsies performed in different ipsilateral lobes, although this approach seems reasonable in cases in which the CT scan pattern differs greatly in different lobes (i.e. pleuroparenchymal fibroelastosis in the upper lobes and reticulation in the lower lobes).

Mediastinal biopsies/aspiration and transcutaneous approach

Endobronchial ultrasonographic fine needle aspiration (FNA) and endo-oesophageal ultrasound FNA have good test performance for diagnosis of sarcoidosis, even in clinically unselected cohorts of patients with intrathoracic lymphadenopathy.[6,34,35] Other ILDs that may present with hilar/mediastinal adenopathies may have a morphological confirmatory diagnosis through these approaches (mycobacterioses, fungal infections, lymphoproliferative disorders).[36,37] Interestingly, EUS may allow the sampling of subdiaphragmatic organs and thus lymphomatoid granulomatosis or other kinds of lymphoproliferative disorders may be diagnosed with biopsies performed in liver, spleen or even adrenal glands.[38] Blinded FNA using 19-G needles is still useful in the same clinico-radiologic context, although its diagnostic yield appears significantly lower.[39] The diagnostic role of these procedures in f-ILD is however irrelevant or minimal. In the majority of cases, enlarged hilar and mediastinal adenopathies may be found in CT scan films of patients with f-ILD, but such moderate enlargement is almost always due to non-specific inflammation.[40] Biopsy of these lymph nodes is therefore of little clinical value except in cases of suspected cancer (as occurs in patients with IPF).[41]

The transcutaneous approach guided by imaging techniques (CT or ultrasound) is used in pulmonary nodules with a very high diagnostic yield in neoplastic lesions even when these lesions measure less than 1 cm. This approach is rarely used in the diagnostic work-up of patients with ILDs, although case reports and a few case series have reported good results mainly in alveolar opacification or when core biopsies with large needles are performed.[42,43]

SLB

According to current guidelines, SLB is still recommended for diagnostic confirmation in a proportion of patients with suspected f-ILD, in particular in the diagnosis of IPF when the HRCT scan pattern is not typical.[3,20] However, two important points need to be considered. Firstly, SLB represents only a small sample of the whole lung and the minimal quantity of lung necessary to guarantee the maximum morphological information compared with the whole lung or lungs remains unknown. Secondly, surgical biopsy may be associated with a significant mortality at 90 days, mainly related to acute exacerbation. Kondoh *et al*. reported that 5 of 236 consecutive patients who underwent SLB experienced an acute exacerbation of IPF following the procedure, with two patients dying within 30 days of the SLB.[44] Utz *et al*. reported a VATS 30-day mortality of 18.8%, with all deaths occurring in patients with UIP/IPF.[45] In a meta-analysis conducted by Nguyen and Myer, a total of 1188 patients undergoing VATS were evaluated and, collectively, 24 patients (2.1%) died within 30 days of the procedure.[46] Another meta-analysis showed that the median diagnostic yield was 95% (range, 42–100%), with IPF as the most frequent diagnosis (33.5%).[46] Notably, neither biopsy site, biopsy number or SLB method were associated with diagnostic accuracy. The pooled postoperative mortality rate for included studies was 3.6% (95% confidence interval, 2.1–5.5), with significant heterogeneity observed. Subgroup analysis revealed that exclusion criteria based on immunocompromised status, mechanical ventilation and severe respiratory dysfunction (diffusing capacity of lung for carbon monoxide <35% or forced vital capacity <55% predicted), but not SLB technique or underlying interstitial lung disease subtype, were possible sources of heterogeneity. Other complications related to SLB are prolonged air leak, persisting pain, fistula and empyema.[47] Given these potential risks and complications, performing a SLB is not always possible due to age, pulmonary disease severity, comorbidities or patient disinclination to undergo the procedure. However, new less surgical invasive approaches are under investigation, with reduced or no assisted ventilation and with expected reduction of acute lung injury mainly related to the lack of requirement for invasive ventilation.[48]

CONCLUSIONS

Semi-invasive or invasive procedures may increase the diagnostic accuracy in patients with suspected f-ILD in which HRCT features are not characteristic. However, any benefits need to be weighed against the risks of the procedures. BAL is the least risky diagnostic procedure. TBB is useful mainly in subjects with HRCT scan documenting alveolar opacification or perilymphatic lines/nodules, but should be avoided in subjects with 'possible' UIP HRCT scan features. Transbronchial cryobiopsy is a new bioptic approach in diffuse parenchymal lung diseases, and is the most likely 'new star in the horizon'. SLB is the most invasive procedure for subjects with f-ILD. Future methodologies might be characterized by a decrease in the use of SLB (due to the high risks of this procedure, mainly in elderly or patients with comorbidities), the introduction of new diagnostic measures (biomarkers, genetic/epigenetic signatures) together with a more precise interpretation of HRCT scan[13,14,49–53] and an increased role of morphology (using traditional or more sophisticated investigative tools). In particular, the morphologic information obtained via these new safer methods will be

© 2015 Asian Pacific Society of Respirology

14401843, 2016, 1, Downloaded from https://onlinelibrary.wiley.com/doi/10.1111/resp.12694 by Universitatsbibliothek RWTH Aachen University, Wiley Online Library on [06/03/2026]. See the Terms and Conditions (https://onlinelibrary.wiley.com/terms-and-conditions) on Wiley Online Library for rules of use; OA articles are governed by the applicable Creative Commons License

	Weight of information (diagnostic confidence)	Need of Semi-invasive procedures	Need of Invasive procedures (Surgical biopsy)
Clinical profile + Lab tests + HRCT features + CLINICAL REASONING	HIGH	+-- (BAL,EUS/EBUS)	-
	MEDIUM	+++ (TBB/c-TBB,BAL)	-
	LOW	++- (c-TBB, new surgical procedures)	++/+++*

*Depending greatly from the patient's inclination , age , morbidities and from the therapeutic options available

Figure 5 Diagnostic algorithm showing the role of semi-invasive and/or invasive procedures in the clinical-radiological scenario of patients with suspected fibrosing interstitial lung disease.

complemented by more informative pathogenetic analysis leading to the diagnosis of f-ILDs.[13,14,54–56] Future studies are required in order to better compare patients' needs, risks and information likelihood provided by different semi-invasive or invasive procedures, the robustness of therapeutic opportunities available and an evaluation for each individual of risks/benefits ratios offered by different levels of diagnostic confidence.[57] Figure 5 shows a possible diagnostic algorithm in which patient inclination, clinical profile (including pulmonary function tests), laboratory tests results and HRCT scan features are compared with the risks and benefits of different invasive procedures.

REFERENCES

1 Poletti V, Chilosi M, Olivieri D. Diagnostic invasive procedures in diffuse infiltrative lung diseases. *Respiration* 2004; **71**: 107–19.
2 Antin-Ozerkis D. Interstitial lung disease: a clinical overview and general approach. In: Grippi MA, Elias JA, Fishman JA, Kotloff RM, Pack AI, Senior RM (eds) Fishman's Pulmonary Diseases and Disorders, Vol. **I**. McGraw Hill, New York, 2015; 810–22.
3 Travis WD, Costabel U, Hansell DM, King TE Jr, Lynch DA, Nicholson AG, Ryerson CJ, Ryu JH, Selman M, Wells AU *et al*. An official American Thoracic Society/European Respiratory Society Statement: update of the International Multidisciplinary Classification of Idiopathic Interstitial Pneumonias. *Am. J. Respir. Crit. Care Med.* 2013; **188**: 733–48.
4 Poletti V, Casoni GL, Gurioli G, Ryu JH, Tomassetti S. Lung cryobiopsies: a paradigm shift in diagnostic bronchoscopy. *Respirology* 2014; **19**: 645–54.
5 Casoni GL, Tomassetti S, Cavazza A, Colby TV, Dubini A, Ryu JH, Carretta E, Tantalocco P, Piciucchi S, Ravaglia C *et al*. Transbronchial lung cryobiopsy in the diagnosis of fibrotic interstitial lung diseases. *PLoS ONE* 2014; **9**: e86716.
6 Annema JT, Rabe KF. State of the art lectures: EUS and EBUS in pulmonary medicine. *Endoscopy* 2006; **38**: S118–22.
7 Fischer A, Antoniou KM, Brown KK, Cadranel J, Corte TJ, du Bois RM, Lee JS, Leslie KO, Lynch DA, Matteson EL *et al*. An official European Respiratory Society/American Thoracic Society research statement: interstitial pneumonia with autoimmune features. *Eur. Respir. J.* 2015; **46**: 976–87.
8 Jacob J, Hansell DM. HRCT of fibrosing lung disease. *Respirology* 2015; **20**: 859–72.
9 Romagnoli M, Nannini C, Piciucchi S, Girelli F, Gurioli C, Casoni G, Ravaglia C, Tomassetti S, Gurioli C, Gavelli G *et al*. Idiopathic nonspecific interstitial pneumonia: an interstitial lung disease associated with autoimmune disorders? *Eur. Respir. J.* 2011; **38**: 384–91.
10 Watadani T, Sakai F, Johkoh T, Noma S, Akira M, Fujimoto K, Bankier AA, Lee KS, Müller NL, Song JW *et al*. Interobserver variability in the CT assessment of honeycombing in the lungs. *Radiology* 2013; **266**: 936–44.
11 Poletti V, Benzaquen S. Transbronchial cryobiopsy in diffuse parenchymal lung disease. A new star in the horizon. *Sarcoidosis Vasc. Diffuse Lung Dis.* 2014; **31**: 178–81.
12 Mark DB, Wong JB. Decision-making in clinical medicine. In: Kasper DL, Fauci AS, Hauser SL, Longo DL, Jameson JL, Loscalzo L (eds) Harrison's Principles of Internal Medicine. Mc Graw Hill, New York, 2015; 18–26.
13 Chilosi M, Carloni C, Rossi A, Poletti V. Premature lung aging and cellular senescence in the pathogenesis of idiopathic pulmonary fibrosis and COPD/emphysema. *Transl. Res.* 2013; **162**: 156–73.
14 Hambly N, Shimbori C, Kolb M. Molecular classification of idiopathic pulmonary fibrosis: personalized medicine, genetics and biomarkers. *Respirology* 2015; **20**: 1010–22.
15 Ryu JH, Olson EJ, Midthun DE, Swensen SJ. Diagnostic approach to the patient with diffuse lung disease. *Mayo Clin. Proc.* 2002; **77**: 1221–7.
16 Oshimo S, Bonella F, Cui A, Beume M, Kohno N, Guzman J, Costabel U. Significance of bronchoalveolar lavage for the diagnosis of idiopathic pulmonary fibrosis. *Am. J. Respir. Crit. Care Med.* 2009; **179**: 1043–7.
17 Kawabata Y, Takemura T, Hebisawa A, Ogura T, Yamaguchi T, Kuriyama T, Nagai S, Sakatani M, Chida K, Sakai F *et al*. Eosinophilia in bronchoalveolar lavage fluid and architectural destruction are features of desquamative interstitial pneumonia. *Histopathology* 2008; **52**: 194–202.
18 Costabel U. CD4/CD8 ratios in bronchoalveolar lavage fluid: of value for diagnosing sarcoidosis? *Eur. Respir. J.* 1997; **10**: 2699–700.
19 Meyer KC, Raghu G, Baughman RP, Brown KK, Costabel U, du Bois RM, Drent M, Haslam PL, Kim DS, Nagai S *et al*. An official American Thoracic Society clinical practice guideline: the clinical utility of bronchoalveolar lavage cellular analysis in interstitial lung disease. *Am. J. Respir. Crit. Care Med.* 2012; **185**: 1004–14.
20 Raghu G, Collard HR, Egan JJ, Martinez FJ, Behr J, Brown KK, Colby TV, Cordier JF, Flaherty KR, Lasky JA *et al*. An official ATS/ERS/JRS/ALAT statement: idiopathic pulmonary fibrosis: evidence-based guidelines for diagnosis and management. *Am. J. Respir. Crit. Care Med.* 2011; **183**: 788–824.
21 Poletti V, Romagna M, Gasponi A, Baruzzi G, Allen KA. Bronchoalveolar lavage in the diagnosis of low-grade, MALT type B-cell lymphoma in the lung. *Monaldi Arch. Chest Dis.* 1995; **50**: 191–4.

 © 2015 Asian Pacific Society of Respirology

14401843, 2016, 1, Downloaded from https://onlinelibrary.wiley.com/doi/10.1111/resp.12694 by Universitatsbibliothek RWTH Aachen University, Wiley Online Library on [06/03/2026]. See the Terms and Conditions (https://onlinelibrary.wiley.com/terms-and-conditions) on Wiley Online Library for rules of use; OA articles are governed by the applicable Creative Commons License

22 Poletti V, Patelli M, Poletti G, Bertanti T, Spiga L. Diffuse panbronchiolitis observed in an Italian. *Chest* 1990; **98**: 515–16.
23 Poletti V, Poletti G, Murer B, Saragoni L, Chilosi M. Bronchoalveolar lavage in malignancy. *Semin. Respir. Crit. Care Med.* 2007; **28**: 534–45.
24 Ryu JH, Mooua T, Daniels CE, Hartman TE, Yi ES, Utz JP, Limper AH. Idiopathic pulmonary fibrosis: evolving concepts. *Mayo Clin. Proc.* 2014; **89**: 1130–42.
25 Andersen HA, Fontana RS, Harrison EG Jr. Transbronchoscopic lung biopsy in diffuse pulmonary disease. *Dis. Chest* 1965; **48**: 187–92.
26 Leslie KO, Gruden JF, Parish JM, Scholand MB. Transbronchial biopsy interpretation in the patient with diffuse parenchymal lung disease. *Arch. Pathol. Lab. Med.* 2007; **131**: 407–23.
27 Poletti V, Patelli M, Poggi S, Bertanti T, Spiga L, Ferracini R. Transbronchial lung biopsy and bronchoalveolar lavage in diagnosis of diffuse infiltrative lung diseases. *Respiration* 1988; **54**: 66–72.
28 Berbescu EA, Katzenstein AL, Snow JL, Zisman DA. Transbronchial biopsy in usual interstitial pneumonia. *Chest* 2006; **129**: 1126–31.
29 Tomassetti S, Cavazza A, Colby TV, Ryu JH, Nanni O, Scarpi E, Tantalocco P, Buccioli M, Dubini A, Piciucchi S *et al.* Transbronchial biopsy is useful in predicting UIP pattern. *Respir. Res.* 2012; **13**: 96.
30 Facciolongo N, Patelli M, Gasparini S, Lazzari Agli L, Salio M, Simonassi C, Del Prato B, Zanoni P. Incidence of complications in bronchoscopy. Multicentre prospective study of 20 986 bronchoscopies. *Monaldi Arch. Chest Dis.* 2009; **71**: 8–14.
31 Poletti V, Hetzel J. Transbronchial cryobiopsy in diffuse parenchymal lung diseases: need of procedural standardization. *Respiration* 2015; **90**: 275–8.
32 Tomassetti S, Wells AU, Costabel U, Cavazza A, Colby TV, Rossi G, Sverzellati N, Carloni A, Carretta E, Buccioli M *et al.* The impact of bronchoscopic lung cryobiopsy in the multidisciplinary diagnosis of idiopathic pulmonary fibrosis. *Am. J. Respir. Crit. Care Med.* 2015 (in press).
33 Casoni GL, Gurioli G, Chhajed PN, Chilosi M, Zompatori M, Olivieri D, Poletti V. The value of transbronchial lung biopsy using jumbo forceps via rigid bronchoscope in diffuse lung disease. *Monaldi Arch. Chest Dis.* 2008; **69**: 59–64.
34 Trisolini R, Lazzari Agli L, Tinelli C, DDe Silvestri A, Scotti V, Patelli M. Endobronchial ultrasound-guided transbronchial needle aspiration for diagnosis of sarcoidosis in clinically unselected study populations. *Respirology* 2015; **20**: 226–34.
35 Fritscher-Ravens A, Sriram PV, Bobrowski C, Pforte A, Topalidis T, Krause C, Jaeckle S, Thonke F, Soehendra N. Mediastinal lymphadenopathy in patients with or without previous malignancy: EUS-FNA-based differential cytodiagnosis in 153 patients. *Am. J. Gastroenterol.* 2000; **95**: 2278–84.
36 Moonim MT, Breen R, Fields PA, Santis G. Diagnosis and subtyping of de novo and relapsed mediastinal lymphomas by endobronchial ultrasound needle aspiration. *Am. J. Respir. Crit. Care Med.* 2013; **188**: 1216–23.
37 Tomlinson GS, Thomas N, Chain BM, Best K, Simpson N, Hardavella G, Brown J, Bhowmik A, Navani N, Janes SM *et al.* Transcriptional profiling of endobronchial ultrasound guided lymph node samples aids diagnosis of mediastinal lymphoadenopathy. *Chest* 2015. doi: 10.1378/chest.15-0647
38 Conti V, Gurioli C, Rossi A, Casoni GL, Piciucchi S, Dubini A, Chilosi M, Poletti V. Value of transesophageal ultrasound (EUS)–guided fine needle aspiration (FNA) in the diagnosis of Lymphomatoid Granulomatosis: a case report. *Rass. Patol. App. Respir.*, fascicolo 1/2015.
39 Bonifazi M, Zuccatosta L, Trisolini R, Moja L, Gasparini S. Transbronchial needle aspiration: a systematic review on predictors of a successful aspirate. *Respiration* 2013; **86**: 123–34.
40 Niimi H, Kang EY, Kwong JS, Carignan S, Muller NL. CT of chronic infiltrative lung disease: prevalence of mediastinal lymphoadenopathy. *J. Comput. Assist. Tomogr.* 1996; **20**: 305–8.
41 Tomassetti S, Gurioli C, Ryu JH, Decker PA, Ravaglia C, Tantalocco P, Buccioli M, Piciucchi S, Sverzellati N, Dubini A *et al.* The impact of lung cancer on survival of idiopathic pulmonary fibrosis. *Chest* 2015; **147**: 157–64.
42 Choi SH, Chae EJ, Kim JE, Kim EY, Oh SY, Hwang HJ, Lee HJ. Percutaneous CT-guided aspiration and core biopsy of pulmonary nodules smaller than 1 cm: analysis of outcomes of 305 procedures from a tertiary referral center. *AJR* 2013; **201**: 964–70.
43 Miao L, Wang Y, Li Y, Ding J, Chen L, Dai J, Cai H, Xiao Y, Cao M, Huang M *et al.* Lesion with morphologic feature of organizing pneumonia (OP) in CT-guided lung biopsy samples for diagnosis of bronchiolitis obliterans organizing pneumonia (BOOP): a retrospective study of 134 cases in a single center. *J. Thorac. Dis.* 2014; **6**: 1251–60.
44 Kondoh Y, Taniguchi H, Kitaichi M, Yokoi T, Johkoh T, Oishi T, Kimura T, Nishiyama O, Kato K, du Bois RM. Acute exacerbation of interstitial pneumonia following surgical lung biopsy. *Respir. Med.* 2006; **100**: 1753–9.
45 Utz JP, Ryu JH, Douglas WW, Hartman TE, Tazelaar HD, Myers JL, Allen MS, Schroeder DR. High short-term mortality following lung biopsy for usual interstitial pneumonia. *Eur. Respir. J.* 2001; **17**: 175–9.
46 Nguyen W, Myer KC. Surgical lung biopsy for the diagnosis of interstitial lung disease: a review of the literature and recommendations for optimizing safety and efficacy. *Sarcoidosis Vasc. Diffuse Lung Dis.* 2013; **30**: 3–16.
47 Han Q, Luo Q, Xie JX, Wu LL, Liao LY, Zhang XX, Chen RC. Diagnostic yield and postoperative mortality associated with surgical lung biopsy for evaluation of interstitial lung diseases: a systematic review and a meta-analysis. *J. Thorac. Cardiovasc. Surg.* 2015; **149**: 1394–401.
48 Pompeo E, Rogliani P, Cristino B, Schillaci O, Novelli G, Saltini C. Awake thoracoscopic biopsy of interstitial lung disease. *Ann. Thorac. Surg.* 2013; **95**: 445–52.
49 Kim SY, Diggans J, Pankratz D, Huang J, Pagan M, Sindy N, Tom E, Anderson J, Choi Y, Lynch DA *et al.* Classification of usual interstitial pneumonia in patients with interstitial lung disease: assessment of a machine learning approach using high-dimensional transcriptional data. *Lancet Respir. Med.* 2015; **3**: 473–82.
50 Jenkins RG, Simpson JK, Saini G, Bentley JH, Russell AM, Braybrooke R, Molyneaux PL, McKeever TM, Wells AU, Flynn A *et al.* Longitudinal change in collagen degradation biomarkers in idiopathic pulmonary fibrosis: an analysis from the prospective, multicentre PROFILE study. *Lancet Respir. Med.* 2015; **3**: 462–72.
51 Wells A, Costabel U, Poletti V, Crestani B, Egan J, Margaritopoulos G, Antoniou K. Challenges in IPF diagnosis, current management and future perspectives. *Sarcoidosis Vasc. Diffuse Lung Dis.* 2015; **32**: 28–35.
52 Kropski JA, Blackwell TS, Loyd JE. The genetic basis of idiopathic pulmonary fibrosis. *Eur. Respir. J.* 2015; **45**: 1717–27.
53 Gruden JF, Panse PM, Leslie KO, Tazelaar HD, Colby TV. UIP diagnosed at surgical lung biopsy, 2000–2009: HRCT patterns and proposed classification system. *AJR* 2013; **200**: W458–67.
54 Chilosi M, Poletti V, Rossi A. The pathogenesis of COPD and IPF: distinct horns of the same devil? *Respir. Res.* 2012; **13**: 3.
55 Lam AP, Herazo-Maya JD, Sennello JA, Flozak AS, Russell S, Mutlu GM, Budinger GR, DasGupta R, Varga J, Kaminski N *et al.* Wnt coreceptor Lrp5 is a driver of idiopathic pulmonary fibrosis. *Am. J. Respir. Crit. Care Med.* 2014; **190**: 185–95.
56 Alder JK, Barkauskas CE, Limjunyawong N, Stanley SE, Kembou F, Tuder RM, Hogan BL, Mitzner W, Armanios M. Telomere dysfunction causes alveolar stem cell failure. *Proc. Natl. Acad. Sci. U.S.A.* 2015; **112**: 5099–104.
57 Kaunisto J, Kelloniemi K, Sutinen E, Hodgson U, Piilonen A, Kaarteenaho R, Mäkitaro R, Purokivi M, Lappi-Blanco E, Saarelainen S *et al.* Re-evaluation of diagnostic parameters is crucial for obtaining accurate data on idiopathic pulmonary fibrosis. *BMC Pulm. Med.* 2015; **15**: 92.

© 2015 Asian Pacific Society of Respirology

14401843, 2016, 1, Downloaded from https://onlinelibrary.wiley.com/doi/10.1111/resp.12694 by Universitatsbibliothek RWTH Aachen University, Wiley Online Library on [06/03/2026]. See the Terms and Conditions (https://onlinelibrary.wiley.com/terms-and-conditions) on Wiley Online Library for rules of use; OA articles are governed by the applicable Creative Commons License